

RESENTING CLINICAL SIGNS

DATE History: Owner had previous sphinx that died of HCM, so Rip is screened yearly. No murmur. Echo last year showed mild to moderate hypertrophy of LV papillary muscles.

8/27/21

ECHOCARDIOGRAPHIC FINDINGS

2D, M-mode, and Doppler study.

PERFORMED BY:

Dr. Meredith Swart

Left atrial size is normal. The mitral valve is normal. Left ventricular wall thickness is normal. Left ventricular dimensions are normal. There is equivocal hypertrophy of the left ventricular papillary muscles. Left ventricular systolic function is normal. The aorta and aortic valve are normal. Right atrial and right ventricular dimensions are normal. The tricuspid valve appears normal, though trace tricuspid regurgitation is present. The pulmonary artery and pulmonic valve are normal. No shunting lesions are visualized. No pericardial effusion or cardiac masses are seen.

INTERPRETED BY

Keith Blass, DVM,
MS, DACVIM
(Cardiology)

IVSd – 4.6 mm
LVPWd – 4.7 mm
LVIDd – 15.1 mm
LVIDs – 8.0 mm
FS – 47%
LVOT – 0.98 m/s
RVOT – 0.83 m/s

PATIENT

Rip Steinmaker

ASSESSMENT/RECOMMENDATIONS

SPECIES

Feline

This examination is equivocal for the presence of cardiac disease, as Rip has only borderline mild hypertrophy of his left ventricular papillary muscles in today's images, therefore, it's unclear whether he truly suffers from a focal version of HCM. If HCM is indeed present, the absence of secondary left atrial dilation suggests that Rip's current risk for the development of congestive heart failure and/or thromboembolic disease appears to be low.

BREED

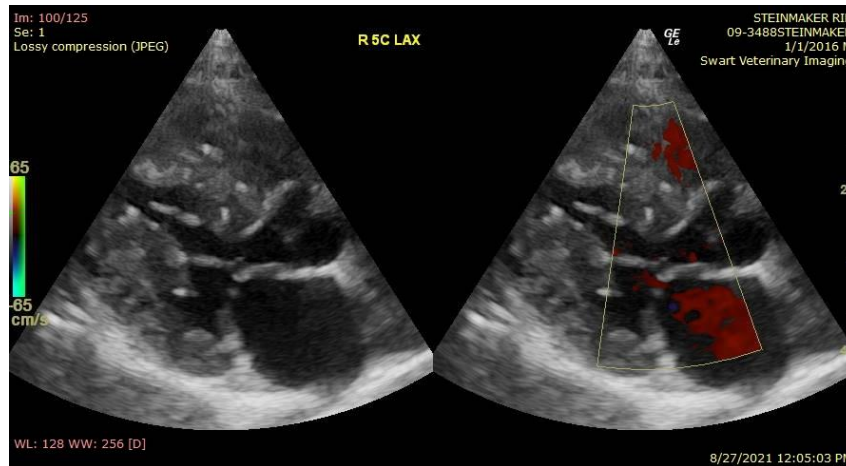
Sphinx

No therapy is recommended based on this exam.

SEX

A recheck echocardiogram is recommended in 12 months, sooner if new clinical signs compatible with cardiac dysfunction develop.

MN



AGE

5 y

WEIGHT

11.5 lb

HOSPITAL NAME

Swart Veterinary
Imaging

REFERRING VET

Dr. Swart

The information and recommendations provided are based on the images presented by the referring veterinarian. No evaluation can be communicated regarding pathology that was not



visible in the image/video clips provided.

DATE

8/27/21

Thank you for this referral. If the clinical or image interpretation does not parallel your findings or if I can be of any further assistance please contact me.

PERFORMED BY:

Keith Blass, DVM, MS, DACVIM (Cardiology)
KeithBlass@gmail.com
631-804-5754

Dr. Meredith Swart

INTERPRETED BY

Keith Blass, DVM,
MS, DACVIM
(Cardiology)

PATIENT

Rip Steinmaker

SPECIES

Feline

BREED

Sphinx

SEX

MN

AGE

5 y

WEIGHT

11.5 lb

HOSPITAL NAME

Swart Veterinary
Imaging

REFERRING VET

Dr. Swart